

# Teratoma of the Greater Omentum Coexistent with an Ovarian Teratoma: A Case Report

Jean Erika Base\* and Angela Aguilar

Cardinal Santos Medical Center, Philippines

## \*Corresponding author

Jean Erika Base, Cardinal Santos Medical Center, Philippines.

Received: September 08, 2025; Accepted: September 16, 2025; Published: September 23, 2025

### ABSTRACT

Extragenadal teratomas are exceedingly rare and the Omentum is the extragenadal place where these teratomas most frequently occur.

We report a case of a 37-year-old patient who presented with intermittent periumbilical pain. Series of imaging studies were done in the span of five years which revealed presence of a teratoma. Intraoperatively, an 8 x 5 cm mass was seen wrapped around the Omentum and distinctly separate from the ovary. The right ovary was cystically enlarged to 7 x 5 cm. Histopathologic examination showed mature cystic teratoma in the right ovary and omental mass. This case report underscores the importance of considering omental teratomas in the differential diagnosis of abdominal masses and highlights the need for a systematic approach to their evaluation and treatment.

**Keywords:** Extragenadal Omental Teratoma, Mature Cystic Teratoma

### Introduction

Extragenadal teratomas are exceedingly rare, only representing 1% to 5 % of all germ cell tumors. The omentum is the most frequent extragenadal place where these teratomas occur [1]. To the best of our knowledge, this is the first documented case of Extragenadal Omental Teratoma in the Philippines.

This is a case of a 37 – year – old primigravid patient with intermittent periumbilical pain over 5 years. A series of imaging studies were done which showed a teratoma change from a 1 x 1 x 1 cm to a 4 x 4 x 3 cm mass in the span of 5 years. No worrisome signs for adnexal malignancy or torsion were observed. Due to its unresolving periumbilical pain, the patient was admitted and underwent exploratory laparotomy. There were two teratomas seen intraoperatively, the right ovary (1) was converted to an enlarged 7 x 5 x 5 cm mass, and (2) an 8 x 7 x 5 cm omental mass. Both masses had hair and calcific materials within, on cut section with histopathologic report of mature cystic teratoma. The postoperative course of the patient was unremarkable.

This case report was made to increase awareness of extragenadal omental teratoma which can (1) present with intermittent abdominal pain, (2) the use of diagnostic tools for identification, (3) the importance of a multi-disciplinary approach and (4) appropriate surgical intervention.

### Case Report

A 37-year-old, primipara, presented with an intermittent, dull, aching, periumbilical pain of 5 - year duration. The patient is obese with BMI of 37 but with no other comorbidities. She sought consult with her OB-GYN for irregular menstruation. A transvaginal ultrasound was done which revealed a thickened endometrium of 1.12 cm and a polycystic right ovary with a dermoid focus measuring only 0.77 x 0.57 x 0.89 cm and a normal left ovary. The patient underwent diagnostic hysteroscopic resection of endometrial polyps which resolved abnormal uterine bleeding. The dermoid focus was managed conservatively with regular imaging surveillance, and particular attention to changes in pain intensity, increase in the size of mass or signs of torsion.

The patient was co-managed with the gastroenterology service due to the intermittent periumbilical pain. She was assessed to

have gastritis which responded to antacids and non-steroidal inflammatory drugs (NSAIDS).

On the day of admission, patient presented a sudden onset of dull, severe periumbilical pain radiating to the hypogastric area. Physical examination revealed a soft and tender abdomen, with no palpable masses. Upon admission, she was given Paracetamol IV where she responded and pain was decreased. She was admitted under the service of Gastroenterology and referred back to GYN service for co-management. Pertinent work-up included normal blood works and pancreatic enzymes. A plain CT scan revealed lobulated complex mass with cystic, soft tissue and peripheral calcific components in the right adnexa measuring 4.9 x 5.3 x 6.2 cm. A smaller, similar-appearing complex nodule is seen inferior to the previously mentioned mass, measuring 2.5 x 2.6 x 3.3 cm. The impression was complex right adnexal masses with cystic, soft tissue and calcific components, representing dermoid cysts. A transvaginal ultrasound was also done which revealed presence of bilateral adnexal cysts. The attending physician considered the possibility of a twisted ovarian cyst, prompting the decision to explore the patient surgically.

Patient underwent exploratory laparotomy under combined epidural and spinal anesthesia. Intraoperatively, the cystic mass was well – defined and encased by the omentum and with thin filmy adhesions around it, and it measured 7 x 6.5 x 5 cm. No attachment to the left ovary was seen. The left ovary was normal and the right ovary was converted into a thin – walled cystic structure measuring 7 x 5 x 5 cm. Both masses have hair and sebum on cut section. Histopathologic examination of the omental mass and the right ovarian cysts were consistent with Mature Cystic Teratomas. The patient had an uneventful post-operative recovery.

## Discussion

The intermittent nature of the abdominal pain in reproductive aged women presents a diagnostic dilemma. Mature Cystic Teratomas typically do not cause symptoms until complications such as torsion, rupture and infection arise. It is widely recognized that teratomas are slow growing lesions from germ cells located in the mature gonads. In early fetal development, germ cells migrate from the yolk sac along the hindgut, following the mesentery route, toward the genital ridge, which is the primitive gonad. These totipotent cells can differentiate into various tissues derived from the three primary embryonic layers [1].

Although mature cystic teratomas are among the most common ovarian tumors, teratomas of extragonadal origin are extremely rare, only representing 1% to 5 % of all germ cell tumors. A review of literature in 2013 done by Ushakov indicated that only 31 cases of teratoma of the greater omentum have been published to date and to the author's knowledge, no other reported cases have been documented in the Philippines [2]. Furthermore, few studies review existence of even less common ectopic sites, including the urinary bladder and the fimbrial end of the fallopian tube [3,4]. The first omental dermoid cyst was described by Lebert in 1734. Kumar et al. and Liu et al [5]. highlight the variability in presentation and the need for a high index of suspicion for accurate diagnosis. Many cases of omental teratomas are discovered incidentally during imaging studies

or intraoperatively during surgeries for presumed different abdominal masses. Extragonadal teratoma in the peritoneum is often referred to as a “wandering teratoma” because it does not remain fixed in one location and can move around within the pelvis [6]. Its etiology is poorly understood and location of the teratomas in the omentum can be explained by three main theories: (1) Primary teratomas might arise from germ cells that have been displaced to the omentum. (2) Teratomas could form in an extra ovary located within the omentum. (3) Teratomas may occur due to the auto-amputation of an ovarian dermoid cyst followed by its secondary implantation into the greater omentum [1].

The third theory, proposed by J.K. Thornton in 1881, suggested that during a slow or long-term process, the tumor might attach itself to nearby structures and develop new blood vessels [6]. In rare cases, the tumor can completely detach from its original connection, becoming a “parasitic teratoma.” These parasitic cystic teratomas are very uncommon, making up only 0.4% of all ovarian teratomas. The greater omentum, which plays a key role in defending against abdominal inflammation and forming adhesions, is likely the primary site for such secondary implantations. This detachment and reattachment of the tumor can happen even without twisting of the adnexa (ovarian structures), and it is believed that new blood vessels and adhesions can form between the tumor and the omentum. This could be most plausible explanation in this index case [7].

Determining a diagnosis before surgery can be challenging. Cystic teratomas can be diagnosed through physical examination and radiologic imaging. Transvaginal ultrasonography is generally preferred over abdominopelvic scans due to its higher sensitivity, comparable to MRI. However, contrast-enhanced CT or MRI of the abdomen and pelvis is the preferred diagnostic modality due to the reduced sensitivity of ultrasound for omental masses [8]. Although in this case, both CT scans done four years apart, identified cystic structures, which were interpreted as adnexal in location.

The chronic pain was likely caused by the mass tugging and pulling on surrounding omentum. In this case, the patient responded well to NSAIDs which was one of the reasons why surgical intervention was delayed. In a study done by Parisien, patients who took anti-inflammatory medications, such as nonsteroidal anti-inflammatory drugs (NSAIDs), faced a higher risk of developing persistent, chronic pain [9]. These reports suggest that while NSAIDs can effectively manage acute pain, their use may contribute to the transition from acute to chronic pain, possibly due to their impact on the pain regulation mechanisms [10].

Surgical resection remains the cornerstone of treatment, with a generally good prognosis for benign tumors.

## Summary

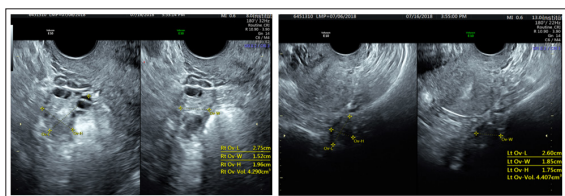
Omental teratomas present unique clinical challenges due to their rarity, varied presentation, and the potential for diagnostic dilemmas. The case report underscores the need for increased vigilance, precise diagnostic methods, collaborative care, and timely surgical management to improve patient outcomes in cases of extragonadal omental teratoma. Patients with omental

teratomas typically present with nonspecific symptoms such as chronic periumbilical pain resolved by NSAIDs. Although transvaginal ultrasound is the preferred reference examination for pelvic organs, CT scan and MRI, are useful for assessing the extent and exact location of the extragonadal teratomas. In cases of persistent but stable presumed benign ovarian tumors smaller than 6 cm, expectant management with follow-up is recommended such as in this case. However, many cases of omental teratomas are discovered incidentally during imaging studies for other conditions or intraoperatively during surgeries for presumed different abdominal masses which highlight the difficulty in diagnosing these extragonadal teratomas.

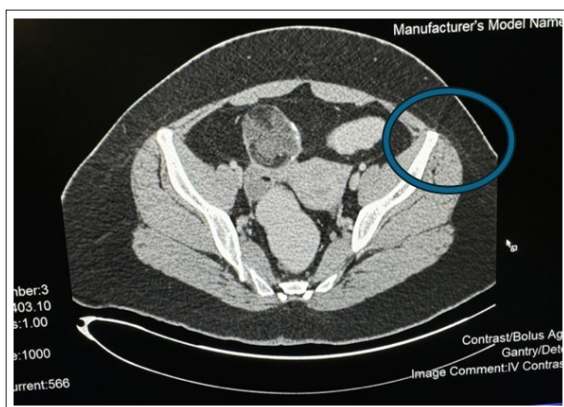
Further research and case documentation are needed to emphasize the need for awareness among clinicians about these atypical presentations.

**Acknowledgments:** None

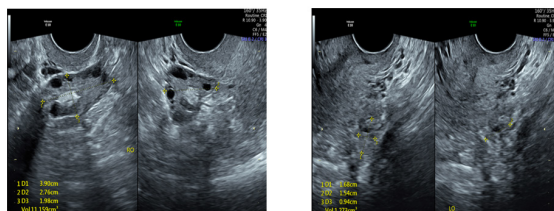
## Appendix



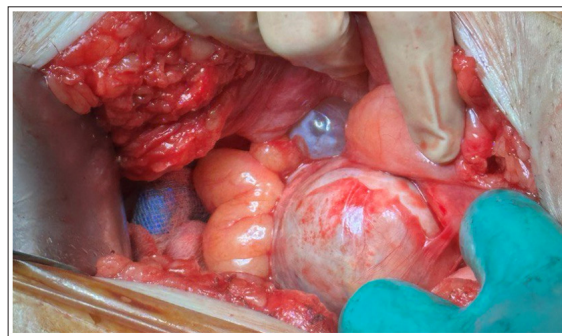
**Figure 1:** A dermoid focus seen on the right ovary in the Transvaginal ultrasound in 2018



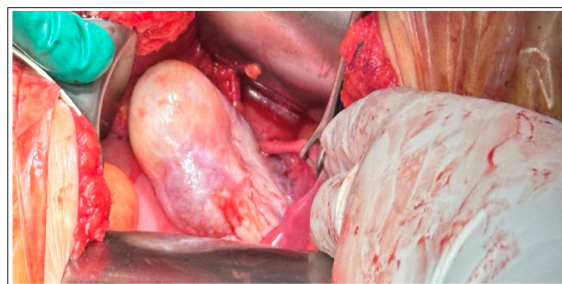
**Figure 2:** A complex mixed attenuating mass at the right adnexal region seen on CT scan in 2019



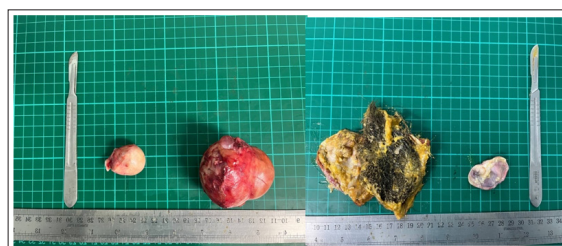
**Figure 3:** Polycystic Right Ovary with Dermoid Focus described in a TVS done in 2020



**Figure 4:** Omental mass measured 8 x 7 x 5 cm



**Figure 5:** Right ovarian cyst seen on the transvaginal ultrasound



**Figure 6:** Both cystic masses were filled with sebum, hair and cartilage on cut section

## References

1. Ali AA, Sall I, El Kaoui H, Bouchentouf SM, El Hjjouji A, et al. Teratoma of the greater omentum. *Canadian Journal of Surgery*. 2009. 52: E54-5.
2. Ushakov F. Parasitic ovarian dermoid tumor of the omentum-A review of the literature and report of two new cases. *European Journal of Obstetrics & Gynecology and Reproductive Biology*. 1998. 81: 77-82.
3. Obstetrical Society of London. *Lancet*. 1903. 162: 26-28.
4. Amr Hassan Wahba. Unreported location and presentation for a parasitic ovarian dermoid cyst: A case report. *Middle East Fertility Society Journal/Middle East Fertility Society Journal*. 2010. 15: 216-218.
5. Li T, Zhang W, Huang J, Shen Y, Cui T, et al. Rare multiple teratomas of the omentum and giant fused teratomas of the bilateral ovaries: a case report and review of the literature. *Gynecology and Pelvic Medicine*. 2021. 25: 4.
6. Topiwala F, Jyoti Gorade, Siddiqui M, Bhat D, Deshpande A. Clinico-histopathological study of gonadal and extragonadal teratomas in tertiary care centre. *International journal of reproduction, contraception, obstetrics and gynecology*. 2024. 13: 904-910.
7. Fabio Rampinelli, Paolo Donarini, Chiara Visenzi, Ficarelli S, Gambino A, et al. The Rare Extragonadal Omental Teratoma: A Case Report. *Journal of minimally invasive gynecology*. 2017. 24: 1046-1048.

8. Srisajjakul S, Prapaisilp P, Bangchokdee S. Imaging features of unusual lesions and complications associated with ovarian mature cystic teratoma. *Clinical imaging*. 2019. 57: 115-123.
9. Parisien M, Lima LV, Dagostino C, El-Hachem N, Drury GL, et al. Acute inflammatory response via neutrophil activation protects against the development of chronic pain. *Science Translational Medicine*. 2022. 11: 14.
10. Torrance A, Hardman J, Taylor L, Coupland A. Lower abdominal pain in fertile females – A diagnostic dilemma in emergency surgery. *International Journal of Surgery*. 2012. 10: S89.