

Novel Modified Ahmed FP-7 Valve with Tube extender for Retrobulbar/Intraconal Surgery in Pseudophakic Advanced Glaucoma; A 1 Year Retrospective Study in 38 Patients

Daniel Laroche MD^{1*} and Brian Grodecki MS²

¹Advanced Eyecare of New York, 215-43 Jamaica Avenue, Queens Village, N.Y. 11428

²Drexel University College of Medicine, 60 N. 36th Street, Philadelphia, PA, 19104

*Corresponding author

Daniel Laroche MD, Advanced Eyecare of New York, 215-43 Jamaica Avenue, Queens Village, N.Y. 11428, New York, USA.

Received: May 11, 2026; Accepted: May 19, 2026; Published: May 26, 2026

ABSTRACT

Purpose: Conventional Ahmed FP-7 valve placement can be limited by hypertensive phase and subconjunctival scarring. We evaluated a retrobulbar/intraconal Ahmed FP-7 technique using a posterior tube extender to divert aqueous humor away from the subconjunctival space and assess 12-month pressure, medication, visual field, and safety outcomes.

Methods: We retrospectively reviewed 38 eyes of 38 pseudophakic patients with refractory glaucoma who underwent Ahmed FP-7 implantation with superotemporal retrobulbar/intraconal plate placement and posterior tube extender at a single center. Outcomes included IOP, IOP-lowering medications, visual field mean deviation (VF MD), best-corrected visual acuity, surgical success, hypertensive phase, and adverse events. Baseline and 12-month values were compared using paired t-tests.

Results: Mean IOP decreased from 24.05 ± 10.58 to 13.39 ± 5.19 mmHg at 12 months (mean change -10.66 mmHg, 95% CI -14.40 to -6.91 , $p = 1.30 \times 10^{-6}$). Mean medication burden decreased from 4.55 ± 1.39 to 1.87 ± 1.83 agents (mean change -2.68 , 95% CI -3.45 to -1.92 , $p = 2.23 \times 10^{-8}$). VF MD remained stable, changing from -21.99 ± 9.54 to -21.79 ± 9.18 dB ($p = 0.794$). Hypertensive phase occurred in 2 eyes (5.3%). Qualified success was achieved in 25 eyes (65.8%) and complete success in 8 eyes (21.1%). No diplopia, motility disturbance, tube or plate exposure, or device removal/revision occurred.

Conclusion: Retrobulbar/intraconal Ahmed FP-7 placement with a posterior tube extender achieved significant IOP and medication reduction with stable visual fields and a low hypertensive-phase rate at 12 months. This technique warrants further evaluation in larger, longer-term studies.

Keywords: Ahmed FP7, Intraconal, Glaucoma, Retrobulbar, Tube extender

Introduction

Glaucoma remains one of the leading causes of irreversible vision loss worldwide [1]. Although topical medications, laser trabeculoplasty, and early lens extraction can successfully manage early-stage disease, a significant proportion of individuals present with advanced glaucoma requiring surgical intervention [2]. For these patients, trabeculectomy and subconjunctival glaucoma drainage devices represent established treatment options, yet both approaches face important limitations [3].

Conventional placement of glaucoma drainage tubes in the subconjunctival space is associated with several complications that can compromise surgical outcomes. Bleb-related issues including bleb leak, encapsulation, blebitis, and giant bleb formation occur when the plate is positioned too superficially or under Tenon's capsule. This placement frequently triggers a hypertensive phase characterized by exuberant subconjunctival scarring, increased medication requirements, and potential surgical failure [4]. Alternative approaches, such as pars plana placement, require complete vitrectomy and carry risks of tube or plate exposure. Inferonasal positioning may cause visible deformity or patient discomfort [5]. Despite refinements in

Citation: Daniel Laroche MD, Brian Grodecki MS. Novel Modified Ahmed FP-7 Valve with Tube extender for Retrobulbar/Intraconal Surgery in Pseudophakic Advanced Glaucoma; A 1 Year Retrospective Study in 38 Patients. *J Opto Opt Res.* 2026. 2(2): 1-9. DOI: doi.org/10.61440/JOOR.2026.v2.12

technique, exposure, erosion, and inadequate pressure control remain significant challenges.

Retrobulbar/intraconal placement of the drainage plate offers a fundamentally different approach by diverting aqueous humor away from the subconjunctival space into the retrobulbar intraconal compartment [6]. This anatomical repositioning addresses several limitations of conventional placement: it bypasses conjunctival scarring common in refractory or multiply-operated eyes, reduces bleb formation and associated complications, and may blunt the hypertensive phase by minimizing the inflammatory response to aqueous in the subconjunctival space and sub tenon's [7]. The retrobulbar space provides a relatively immune-privileged alternative reservoir for aqueous drainage that may improve device longevity and functional outcomes [8]. Potential complications of this approach include motility disturbances, retrobulbar hemorrhage, and the technical complexity of posterior placement, though careful surgical technique can mitigate these risks [9].

Our preliminary investigation demonstrated the feasibility of retrobulbar/intraconal Ahmed FP-7 placement with a posterior tube extender in four patients, showing favorable intraocular pressure control and reduced medication dependence. The present study expands this experience to 38 pseudophakic eyes of patients with refractory glaucoma, most of whom were Black/African American and had primary open-angle glaucoma, evaluating both the safety and efficacy of this technique over a 12-month period. Specific objectives include assessing IOP reduction, medication burden, visual field stability, best-corrected visual acuity, surgical success, and postoperative adverse events, including the hypertensive phase.

Materials and Methods

Study Design and Setting

This retrospective case series analyzed 38 consecutive eyes of 38 patients who underwent retrobulbar/intraconal Ahmed FP-7 valve implantation with posterior tube extender between May 1, 2020, and August 7, 2023, at Advanced Eyecare of New York, performed by a single surgeon. This study received a waiver of informed consent and was approved by the Institutional Review Board of the New York Eye and Ear Infirmary of Mount Sinai (IRB STUDY23-00815). All procedures conformed to the Declaration of Helsinki, relevant laws, and institutional policies.

Patient Selection

Inclusion criteria were: (1) adult patients (age ≥ 18 years) with refractory glaucoma despite maximal tolerated medical therapy, defined as uncontrolled IOP on ≥ 3 topical medications or documented intolerance to additional agents; (2) pseudophakic status to permit ciliary sulcus tube placement; (3) absence of orbital masses on clinical examination; (4) minimum 12-month follow-up; and (5) adequate clinical documentation at baseline and follow-up visits. Patients with prior glaucoma surgery (trabeculectomy, tube shunt, or minimally invasive procedures) were included. Exclusion criteria were: (1) age < 18 years, (2) phakic or aphakic eyes, (3) orbital pathology, and (4) loss to follow-up before 12 months.

Comprehensive screening and exclusion data were not available for the full study period. The final analysis included

38 eyes of 38 patients. The cohort was predominantly Black/African American and included multiple glaucoma subtypes, as summarized in Table 1. When both eyes met inclusion criteria, the first operated eye was included. At baseline, reliably available variables included age, sex, race/ethnicity, glaucoma diagnosis, BCVA, IOP, number and classes of IOP-lowering medications, and VF MD. Glaucoma duration, prior ocular procedures, and timing of cataract surgery relative to tube implantation were incompletely documented and were not included in the final baseline characteristics table.

Table 1: Baseline Characteristics of Included Patients

Characteristic	n	Value
Demographics		
Age, years, mean \pm SD	38	71.9 \pm 9.3
Sex, n (%)	38	
Male	12	31.6%
Female	26	68.4%
Race/ethnicity, n (%)	38	
Black/African American, non-Hispanic	34	89.5%
Black/African American, Hispanic/Latino	1	2.6%
White/Caucasian	2	5.3%
Mexican American, Hispanic/Latino	1	2.6%
Ocular characteristics		
Lens status, n (%)	38	
Pseudophakic	38	100.0%
Glaucoma type, n (%)	38	
Primary open-angle glaucoma	29	76.3%
Chronic angle-closure glaucoma	6	15.8%
Acute angle-closure glaucoma	1	2.6%
Ocular hypertension	1	2.6%
Glaucoma secondary to ocular inflammation	1	2.6%
Baseline disease severity		
Baseline IOP, mmHg, mean \pm SD	38	24.1 \pm 10.6
Baseline IOP, mmHg, median	38	22.0
Baseline IOP-lowering meds, n, mean \pm SD	38	4.6 \pm 1.4
Baseline IOP-lowering meds, n, median	38	4.0
Baseline BCVA, logMAR, mean \pm SD	34*	0.56 \pm 0.60
Baseline BCVA, logMAR, median	34*	0.40
Baseline visual field MD, dB, mean \pm SD	38	-22.0 \pm 9.5
Baseline visual field MD, dB, median	38	-24.23

Abbreviations: BCVA = best-corrected visual acuity; IOP = intraocular pressure; MD = mean deviation; SD = standard deviation.

*BCVA logMAR summary includes only eyes with numeric logMAR acuity values available in the dataset. Eyes with qualitative acuity values, including CF, HM, LP, or NLP, were excluded from this continuous summary.

Outcome Measures

The primary outcome was change in IOP from baseline to 12 months. Secondary outcomes included: (1) change in number of IOP-lowering medications, (2) change in VF MD, (3) change in BCVA, and (4) incidence of adverse events. Surgical success was defined as an IOP reduction of $\geq 20\%$ from baseline and IOP between 6–21 mmHg with or without medications, without loss of light perception vision or need for additional glaucoma surgery. Qualified success permitted adjunctive medications; complete success required no medications. Failure was defined as IOP > 21 mmHg or < 6 mmHg on two consecutive visits after 3 months, IOP reduction of $< 20\%$ from baseline, loss of light perception, or need for additional glaucoma surgery.

Adverse events were abstracted from available retrospective chart documentation. Specific complications monitored included: hypertensive phase (IOP > 21 mmHg between postoperative days 7 and 90 after initial postoperative IOP reduction, not attributable to tube obstruction, tube retraction, or valve malfunction), tube malposition or obstruction, corneal decompensation, diplopia or motility disturbance, retrobulbar hemorrhage, choroidal effusion, endophthalmitis, and implant exposure or migration.

Follow-up Schedule

Patients were examined at postoperative day 1, week 1, months 1, 3, 6, 9, and 12, although visit timing varied due to the retrospective nature of the study. At each visit, IOP was measured by Goldmann applanation tonometry, medications were recorded, and adverse events were documented when available. BCVA was assessed at months 1, 3, 6, and 12. Visual field testing was performed at baseline and 12 months, with additional testing at 6 months when clinically indicated.

Surgical Technique

The Ahmed FP-7 valve (New World Medical, Inc, Rancho Cucamonga, CA, USA) with silicone tube extender (300-micrometer lumen; New World Medical, Inc) was used in all cases. The surgical technique was standardized throughout the study period and no major deviations were noted. The surgeon had performed four prior retrobulbar tube placements before study initiation.

The operative eye was prepped with povidone-iodine, draped in sterile fashion, and a lid speculum was placed. A double-armed 8-0 Vicryl traction suture was passed through the superior corneal stroma to infraduct the globe, and a superotemporal conjunctival peritomy was created. The Ahmed FP-7 valve was primed by flushing approximately 1 mL of balanced salt solution through a 27-gauge cannula to verify unobstructed flow.

A 10-0 Prolene suture secured the silicone tube extender tip just behind the valve using a 3-1-1 knot, and an additional

10-0 Prolene suture was placed near the valve exit to anchor the extender posterior to the valve orifice. The posterior portion of the extender was guided through the central opening of the Ahmed FP-7 plate. Large curved Stevens scissors were used to bluntly dissect posteriorly into the retrobulbar/intraconal space beyond Tenon's capsule. The assembled valve and extender were inserted into the superotemporal quadrant, advanced as far posteriorly as possible, and positioned freely in the intraconal space between the superior and lateral rectus muscles.

The anterior tube tip was beveled at a 5-degree angle to prevent iris obstruction. After measuring 1.5 mm from the limbus superotemporally with calipers, a 23-gauge needle tract was created into the ciliary sulcus. The tube was placed behind the iris and anterior to the intraocular lens, outside the pupillary axis. A 10-0 Prolene suture (3-1-1 knot) secured the tube to the sclera at the entry point, and a second 10-0 Prolene suture was placed approximately 10 mm from the limbus for additional stabilization.

A 4×8 mm scleral patch graft (Katena, large corneal scleral patch) trimmed with Stevens scissors was placed over the anterior tube and anchored with four 8-0 Vicryl interrupted sutures. The conjunctiva was advanced anteriorly to achieve complete graft coverage and secured with two locking running 8-0 Vicryl sutures. Intracameral moxifloxacin and subconjunctival triamcinolone were administered at case completion.

Postoperative Management

All preoperative IOP-lowering medications were discontinued immediately after surgery. The standardized postoperative regimen consisted of prednisolone acetate 1% four times daily, ketorolac 0.5% three times daily, and ofloxacin 0.3% four times daily. Topical corticosteroids were tapered over 8–12 weeks based on anterior chamber inflammation. IOP-lowering medications were reintroduced at the surgeon's discretion based on postoperative IOP, optic nerve status, and overall clinical assessment.

Statistical Analysis

Continuous variables (IOP, number of medications, VF MD, BCVA) were summarized as mean \pm standard deviation and 95% confidence interval, and as median with interquartile range. Distributions were inspected visually, and normality of within-eye differences was assessed with the Shapiro-Wilk test. Because all within-eye differences met normality assumptions ($p > 0.05$ for all Shapiro-Wilk tests), parametric testing was used.

The primary analysis compared baseline and 12-month values using paired t-tests on within-eye differences. Change was defined as 12-month value minus baseline value. Mean change is reported with 95% confidence intervals derived from the t distribution. All analyses were performed on available data at each time point and no patients were excluded after enrollment. All included eyes had at least 12 months of follow-up. Missing data for secondary outcomes were handled using complete-case analysis, with each outcome analyzed using available data at the relevant time point. BCVA was analyzed continuously only for eyes with numeric logMAR values. Eyes with qualitative acuity values, including CF, HM, LP, or NLP, were excluded from continuous paired logMAR analysis and evaluated descriptively.

Qualitative acuity categories were not converted to numeric logMAR values. Two-sided p-values <0.05 were considered statistically significant. Analyses were conducted in Python version 3.11 using SciPy, NumPy, Pandas, and Statsmodels.

Results

Patient Characteristics

Thirty-eight eyes of 38 patients met inclusion criteria and completed 12-month follow-up with no losses to follow-up. Baseline demographic and clinical characteristics are summarized in Table 1. Mean age was 71.9 ± 9.3 years (range 53–96). Twelve patients (31.6%) were male and 26 (68.4%) were female. Thirty-four patients (89.5%) were Black/African American and non-Hispanic, 1 (2.6%) was Black/African American and Hispanic/Latino, 2 (5.3%) were White/Caucasian, and 1 (2.6%) was Mexican American and Hispanic/Latino. Primary open-angle glaucoma was the most common diagnosis, present in 29 eyes (76.3%), followed by chronic angle-closure glaucoma in 6 eyes (15.8%), acute angle-closure glaucoma in 1 eye (2.6%), ocular hypertension in 1 eye (2.6%), and glaucoma secondary to ocular inflammation in 1 eye (2.6%). All eyes were pseudophakic.

Intraocular Pressure

Mean IOP decreased significantly from 24.05 ± 10.58 mmHg at baseline to 13.39 ± 5.19 mmHg at 12 months, representing a mean change of -10.66 mmHg (95% CI -14.40 to -6.91 , $p = 1.30 \times 10^{-6}$) (Figure 1). Median IOP decreased from 22.00 mmHg (IQR 17.25–28.00) to 13.00 mmHg (IQR 10.00–16.00). Thirty-four eyes (89.5%) demonstrated IOP reduction from baseline. Thirty-five eyes (92.1%) achieved IOP ≤ 18 mmHg, and 25 eyes (65.8%) achieved IOP ≤ 15 mmHg at 12 months.

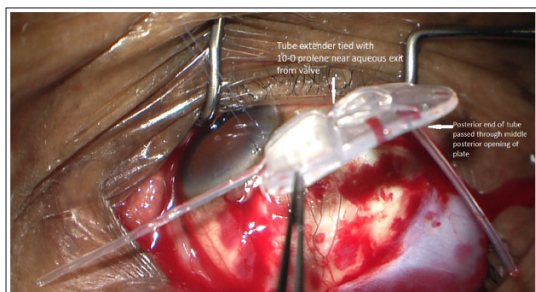


Figure 1: Placement of the Ahmed FP-7 valve.

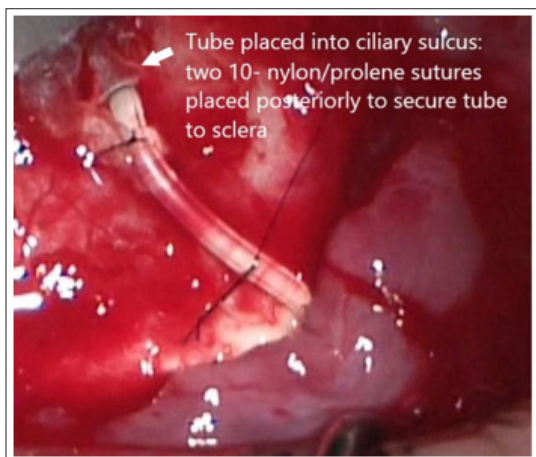


Figure 2: Retrobulbar tube extender placement

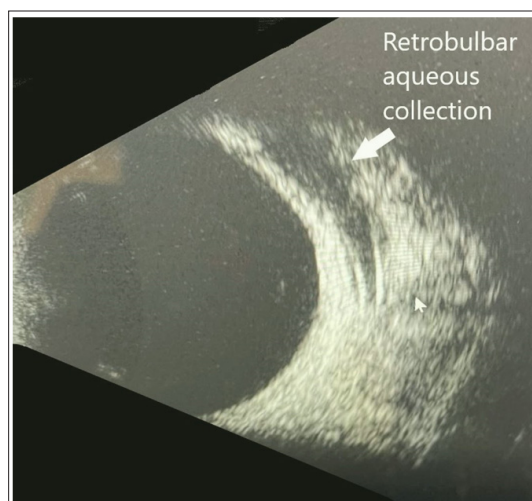


Figure 3: B-Scan showing aqueous collection in retrobulbar space.

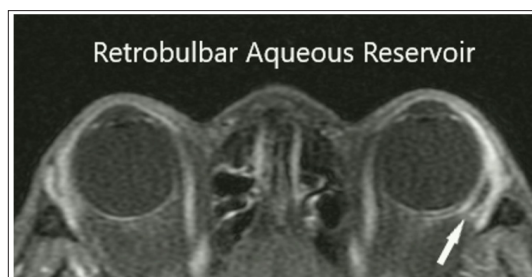


Figure 4: MRI showing aqueous in retrobulbar space.

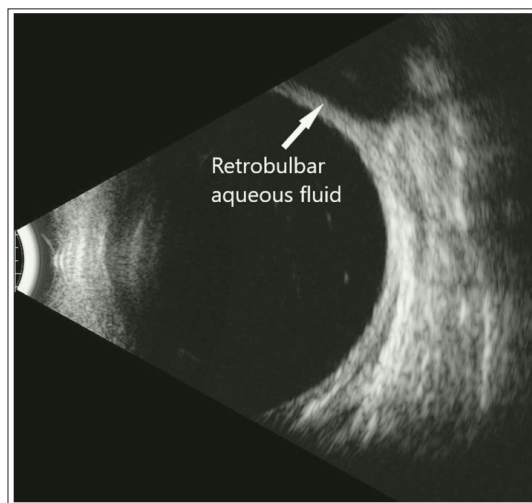


Figure 5: B-scan of aqueous in retrobulbar space.

Hypertensive Phase

Two eyes (5.3%) met criteria for hypertensive phase, defined as IOP >21 mmHg between postoperative days 7 and 90 after initial postoperative IOP reduction and not attributable to tube obstruction, tube retraction, or valve malfunction. Both cases are summarized in Table 3.

Glaucoma Medications

The number of IOP-lowering medications decreased significantly from 4.55 ± 1.39 agents at baseline to 1.87 ± 1.83 agents at 12 months, representing a mean change of -2.68 agents (95% CI -3.45 to -1.92 , $p = 2.23 \times 10^{-8}$). Median medications decreased from 4.00 (IQR 3.25–6.00) to 2.00 (IQR 0.00–3.00). Fourteen eyes (36.8%) were medication-free at 12 months.

Surgical Success

Surgical outcomes at 12 months are summarized in Table 2. Using predefined success criteria of IOP 6–21 mmHg with $\geq 20\%$ reduction from baseline, 25 eyes (65.8%) achieved qualified success with or without medications, and 8 eyes (21.1%) achieved complete success without medications. Ten eyes (26.3%) did not achieve $\geq 20\%$ IOP reduction at 12 months. Two eyes (5.3%) had loss of light perception at 12 months with baseline BCVA of HM and 20/400 in these eyes with severely advanced glaucoma.

Table 2: Surgical and Functional Outcomes at 12 Months

A. Continuous clinical outcomes							
Outcome	n	Baseline, mean \pm SD	Baseline, median [IQR]	12 months, mean \pm SD	12 months, median [IQR]	Mean change (95% CI)	P-value
IOP, mmHg	38	24.05 \pm 10.58	22.00 [17.25 to 28.00]	13.39 \pm 5.19	13.00 [10.00 to 16.00]	-10.66 (-14.40 to -6.91)	1.30×10^{-6}
IOP-lowering medications, n	38	4.55 \pm 1.39	4.00 [3.25 to 6.00]	1.87 \pm 1.83	2.00 [0.00 to 3.00]	-2.68 (-3.45 to -1.92)	2.23×10^{-8}
Visual field MD, dB	38	-21.99 \pm 9.54	-24.23 [-30.00 to -15.77]	-21.79 \pm 9.18	-24.09 [-29.46 to -14.30]	+0.20 (-1.37 to +1.78)	0.794
BCVA, logMAR, paired numeric eyes only	29	0.40 \pm 0.39	0.30 [0.10 to 0.60]	0.43 \pm 0.38	0.30 [0.10 to 0.70]	+0.02 (-0.06 to +0.11)	0.553
BCVA, logMAR, numeric values available	34 / 30	0.56 \pm 0.60	0.40 [0.10 to 0.81]	0.48 \pm 0.47	0.30 [0.12 to 0.70]	Not paired	—

B. BCVA line-change outcomes	
BCVA line-change outcome among paired numeric eyes	n (%)
Gained ≥ 2 Snellen lines	5 (17.2%)
Stable within 2 Snellen lines	18 (62.1%)
Lost ≥ 2 Snellen lines	6 (20.7%)

C. Surgical success outcomes	
Surgical outcome at 12 months	n (%)
Qualified success	25 (65.8%)
Complete success	8 (21.1%)
Did not achieve $\geq 20\%$ IOP reduction	10 (26.3%)
Loss of light perception	2 (5.3%)

Abbreviations: BCVA = best-corrected visual acuity; CI = confidence interval; IOP = intraocular pressure; MD = mean deviation.

Change was calculated as the 12-month value minus the baseline value. For IOP and medication burden, negative values indicate reduction. For logMAR BCVA, negative change indicates visual improvement and positive change indicates visual worsening. For visual field MD, positive values indicate improvement.

BCVA continuous paired analysis included only eyes with paired numeric logMAR values at baseline and 12 months. Eyes with CF, HM, LP, or NLP acuity at either time point were excluded from continuous paired logMAR analysis.

The descriptive BCVA row shows all available numeric logMAR values at each time point and is not a paired comparison.

Qualified success was defined as IOP 6–21 mmHg with $\geq 20\%$ reduction from baseline, with or without medications, and without loss of light perception or additional glaucoma surgery. Complete success met the same criteria without medications.

Visual Field

Visual field mean deviation (VF MD) data were available for all 38 eyes with paired testing at baseline and 12 months. VF MD remained stable. Baseline mean VF MD was -21.99 ± 9.54 dB, with median -24.23 dB (IQR -30.00 to -15.77). At 12 months, mean VF MD was -21.79 ± 9.18 dB, with median -24.09 dB (IQR -29.46 to -14.30). The mean change was $+0.20$ dB (95% CI -1.37 to $+1.78$, $p = 0.794$), indicating no significant progression.

Visual Acuity

Among eyes with numeric logMAR measurements available, mean BCVA was 0.56 ± 0.60 logMAR (Snellen equivalent approximately 20/70) at baseline and 0.48 ± 0.47 logMAR (Snellen equivalent approximately 20/60) at 12 months. Among the 29 eyes with paired numeric logMAR measurements included in continuous BCVA change analysis, mean change was $+0.02$ logMAR (95% CI, -0.06 to $+0.11$, $p = 0.553$). Five eyes (17.2%) gained ≥ 2 Snellen lines, 18 eyes (62.1%) remained stable, and 6 eyes (20.7%) lost ≥ 2 Snellen lines. Eyes with acuity recorded as CF, HM, LP, or NLP at either time point were excluded from continuous logMAR analysis.

and evaluated descriptively. Among these eyes, outcomes were heterogeneous and included 2 eyes with NLP at 12 months (pre-op BCVA of HM and 20/400), 4 eyes with HM at 12 months (1 pre-op BCVA of HM, 1 of LP, and 2 of CF at one foot), 2 eyes with CF at 12 months (1 pre-op VA of 20/50 and 1 of 20/200), and 1 eye that improved from CF to 2.0 logMAR.

Adverse Events

Adverse events are summarized in Table 3. Documented postoperative adverse events included hypertensive phase in 2 eyes (5.3%), hypotony in 2 eyes (5.3%), choroidal effusion in 2 eyes (5.3%), peripheral anterior synechiae or synechiae in 2 eyes (5.3%), shallow anterior chamber in 1 eye (2.6%), viscoelastic retention in 1 eye (2.6%), and hyphema in 1 eye (2.6%). One eye with a shallow anterior chamber, hypotony, and synechiae underwent synechiolysis on 08/08/2023.

Table 3: Documented Postoperative Adverse Events

Complication	n	%
Documented postoperative adverse events		
Hypertensive phase	2	5.3%
Hypotony	2	5.3%
Choroidal effusion	2	5.3%
Peripheral anterior synechiae/ synechiae	2	5.3%
Shallow anterior chamber	1	2.6%
Viscoelastic retention	1	2.6%
Hyphema	1	2.6%
Diplopia or motility disturbance	0	0.0%
Tube or plate exposure	0	0.0%
Device removal or revision	0	0.0%

Abbreviations: IOP = intraocular pressure.

Adverse events were abstracted from retrospective chart documentation among the final 38 included eyes. Individual eyes may have contributed to more than one adverse-event category.

Hypertensive phase was defined as IOP >21 mmHg between postoperative days 7 and 90 after initial postoperative IOP reduction and not attributable to tube obstruction, tube retraction, or valve malfunction.

One eye with shallow anterior chamber, hypotony, and synechiae underwent synechiolysis on 08/08/2023.

No cases of diplopia, motility disturbance, tube or plate exposure, tube malposition, tube obstruction, corneal decompensation, endophthalmitis, suprachoroidal hemorrhage, or retrobulbar hemorrhage occurred. No eyes required device removal or revision.

Discussion

In this cohort of 38 pseudophakic eyes from 38 patients with refractory glaucoma, retrobulbar/intraconal placement of the Ahmed FP-7 valve with a tube extender achieved statistically significant and clinically meaningful reductions in both

IOP and medication burden at 12 months. The cohort was predominantly Black/African American, with primary open-angle glaucoma representing the most common diagnosis, although other glaucoma subtypes were also included. These results are particularly noteworthy given that African American patients have historically demonstrated lower success rates with conventional Ahmed valve implantation compared to white patients, with one study reporting African American race as a significant risk factor for surgical failure [10]. A systematic review similarly found that glaucoma surgical outcomes in patients of Afro-Caribbean descent appear poorer overall, particularly for trabeculectomy, though evidence for aqueous shunts was more equivocal [11].

Comparison to Published Outcomes

The 12-month IOP of 13.39 mmHg achieved in this series compares favorably with published outcomes after conventional Ahmed valve placement. The Ahmed Versus Baerveldt Study 5-year pooled analysis reported mean IOP of 15.8 mmHg in the Ahmed group [12]. A long-term study of 302 eyes with conventional Ahmed placement reported IOP of 14.2 mmHg at 15 years [13]. The medication reduction from 4.55 to 1.87 agents in our series also compares well to the Ahmed group's 1.9 medications at 5 years in the Ahmed Versus Baerveldt Study [12]. These comparisons suggest that retrobulbar placement can achieve IOP outcomes similar to or better than those reported with conventional placement, although direct comparison is limited by differences in study design, follow-up duration, and patient populations.

Low Incidence of Hypertensive Phase

A notable finding of this study is the low incidence of documented postoperative hypertensive phase (HP). Two eyes (5.3%) met criteria for HP, defined as IOP >21 mmHg occurring between postoperative days 7 and 90. This rate remains substantially lower than published HP incidence rates of 56%–82% after conventional Ahmed valve placement. A recent study of 193 eyes with conventional Ahmed placement found HP in 58% of patients, with higher baseline IOP and younger age as risk factors. Another landmark study reported HP in 82% of patients, peaking at 1 month postoperatively. A 2024 study found that HP significantly increases failure risk, with only 52.6% success at 2 years in HP eyes versus 76.3% in non-HP eyes. The clinical significance of HP extends beyond IOP control. In Black and Hispanic patients specifically, HP has been identified as a major risk factor for vision loss, with an odds ratio of 4.71 for losing ≥ 2 Snellen lines at 1 year. The low rate of documented HP in this series may therefore be particularly advantageous in populations at higher risk for HP-related vision loss. However, this finding should be interpreted cautiously given the retrospective design, modest sample size, and absence of a conventional-placement control group. We hypothesize that the low incidence of HP with retrobulbar placement may result from bypassing the subconjunctival space, where fibroblast proliferation and capsule formation around the plate are believed to drive this. By positioning the plate in the intraconal/retrobulbar compartment beyond Tenon's capsule, aqueous drains into a space with potentially less fibrogenic potential, thereby reducing the bleb-related scarring thought to contribute to HP.

Mechanism of Aqueous Absorption

The mechanism by which aqueous humor is absorbed from the retrobulbar space warrants consideration. Recent research has identified lymphatic channels in the ciliary body (the “uveolymphatic pathway”) and demonstrated active lymphatic drainage from the anterior chamber to cervical lymph nodes in animal models. A 2024 review characterized aqueous humor as functionally analogous to lymph, with drainage occurring through both venous and lymphatic systems [14,15]. Multiple unconventional outflow pathways have been described, including the uveoscleral pathway where aqueous drains across the sclera to be resorbed by orbital vessels, and a uveovortex pathway where aqueous enters the choroid to drain through vortex veins [16].

However, the specific mechanism of aqueous absorption from the retrobulbar space following tube shunt placement remains incompletely characterized. Classic studies found limited lymphatic drainage from orbital fat within 6 hours of injection [17]. Potential pathways include absorption by the orbital venous plexus, diffusion into surrounding orbital tissues, or lymphatic uptake via channels associated with the optic nerve sheath. Further imaging studies using modalities such as MRI or ultrasound biomicroscopy are needed to elucidate the outflow dynamics in this novel anatomical compartment.

Safety Considerations

Positioning the plate in the retrobulbar/intraconal compartment raises theoretical concerns regarding optic nerve compression and extraocular muscle dysfunction [18,19]. Importantly, no cases of optic nerve impingement, compression-related adverse effects, diplopia, or motility disturbance were documented in this series. No tube or plate exposure and no device removal or revision occurred. The plate was able to float freely within the retrobulbar compartment, and in situations where anatomical space was limited, the implant could be carefully trimmed to optimize fit without compromising orientation or function.

To ensure safe and effective positioning, we developed the Laroche Formula, defined as $(\frac{1}{2} \times \text{axial length}) \times \pi - 3$, for determining optimal retrobulbar tube plate length [20]. This calculation was designed to position the plate between the globe’s equator and the optic nerve, thereby reducing concern for potential optic nerve contact. Applying these criteria, we have refined our technique such that a tube extender is no longer necessary in our current practice. The native tube length, plate positioning, and surgical approach now provide adequate reach in appropriately selected eyes.

Adverse events were generally transient and manageable. Documented postoperative events included hypertensive phase in 2 eyes, hypotony in 2 eyes, choroidal effusion in 2 eyes, peripheral anterior synechiae or synechiae in 2 eyes, shallow anterior chamber in 1 eye, viscoelastic retention in 1 eye, and hyphema in 1 eye. The two choroidal effusions represent a recognized complication of glaucoma surgery when IOP is lowered significantly. One eye with shallow anterior chamber, hypotony, and synechiae required synechiolysis. To mitigate this risk, we now routinely perform prophylactic inferior sclerotomy approximately 5 mm from the limbus and retain viscoelastic in

the anterior chamber at case completion [24]. All tubes were placed in the ciliary sulcus in pseudophakic patients, minimizing corneal endothelial contact and reducing the risk of long-term endothelial cell loss compared with anterior chamber placement [21].

Advantages Over Conventional Placement

Retrobulbar/intraconal tube placement offers several potential advantages over traditional subconjunctival shunt procedures. By eliminating bleb formation, this technique avoids bleb-related complications including bleb leak, blebitis, and bleb encapsulation [22]. It also eliminates the need for bleb needling, which can introduce additional complications such as infection, hypotony, or further scarring. This approach may be particularly valuable in salvaging previously fibrotic or failing devices by redirecting aqueous flow into the retrobulbar space, thereby restoring function without relying on compromised subconjunctival tissues.

Clinical Implications

Given these promising results, retrobulbar/intraconal implantation may merit further consideration as a potential primary surgical option for patients with advanced or refractory glaucoma, particularly those at high risk of conjunctival scarring or bleb failure. This includes patients with a history of multiple prior surgeries, underlying inflammatory disease, or African ancestry, a population that bears a disproportionate glaucoma burden and remains underrepresented in many glaucoma surgical studies. The low rate of documented HP in our series is particularly relevant for this population, given the strong association between HP and vision loss in Black and Hispanic patients.

Limitations

Several limitations warrant consideration. First, this was a retrospective, single-surgeon case series, which introduces potential selection bias and limits generalizability. Comprehensive screening and enrollment data were not available, precluding accurate reporting of the total number of patients assessed, the number excluded, and the reasons for exclusion. As a result, we could not fully evaluate how patients selected for this technique may have differed from those treated with conventional glaucoma drainage device placement. Second, several clinically relevant baseline variables were incompletely documented or unavailable, including glaucoma duration, history of prior glaucoma procedures such as trabeculectomy, prior tube shunt, minimally invasive glaucoma surgery, or laser trabeculoplasty, and the timing of cataract surgery relative to tube implantation. The absence of these variables limits assessment of their potential influence on surgical outcomes and makes comparison with prior studies less precise. Third, the retrospective chart review design introduced inherent constraints, including possible inconsistencies in documentation, lack of standardized measurement protocols, and variable follow-up intervals. In addition, escalation or reintroduction of glaucoma medications was not governed by a predefined protocol, which may have introduced treatment bias and could confound interpretation of surgical efficacy. The absence of a control group further limits the ability to directly compare retrobulbar/intraconal placement with conventional subconjunctival Ahmed valve implantation in a similar patient population.

Fourth, the cohort size was modest and drawn from a single clinical practice. Although the study provides valuable data from a population with substantial representation of Black patients, the findings may not generalize to broader patient populations, other glaucoma subtypes, or surgeons with different levels of experience using this technique. The learning curve for retrobulbar/intraconal implantation has not been formally assessed. Technical refinements were also made during and after the study period, including development of the Laroche Formula and subsequent elimination of the tube extender requirement in current practice. Fifth, interpretation of progression to NLP vision is limited by the advanced baseline disease severity and poor presenting visual acuity in this cohort. The observed 5.3% NLP rate should therefore be interpreted in the context of baseline visual potential rather than attributed solely to the surgical technique. Prior studies have identified poor preoperative visual acuity as an important predictor of progression to NLP after glaucoma drainage device surgery. In the Ahmed Baerveldt Comparison Study, the overall NLP or safety-related failure rate was 7.7% in the Ahmed glaucoma valve group, although that cohort included eyes with better baseline visual acuity [23]. In contrast, studies of neovascular glaucoma and other high-risk populations with poor baseline vision have reported NLP rates of approximately 14.8%–18.7% [24]. Thus, the rate of progression to NLP observed in the present series appears broadly consistent with outcomes reported in advanced, high-risk glaucoma populations, but direct comparison is limited by differences in baseline vision, glaucoma subtype, and study design. Finally, follow-up was limited to 12 months, which may not capture late failures, delayed complications, implant migration or exposure, endothelial cell loss, or longer-term durability of IOP control. Larger multicenter studies with standardized follow-up, predefined medication-escalation criteria, and longer observation periods are needed to validate these findings and determine whether retrobulbar/intraconal Ahmed valve placement offers sustained advantages over conventional placement.

Future Directions

Longer-term follow-up and larger, multicenter studies are necessary to fully assess the durability and generalizability of this technique. Imaging-based investigations using MRI or ultrasound biomicroscopy could provide valuable insights into aqueous outflow dynamics in the retrobulbar space and clarify the impact of anatomical factors, such as axial length, on surgical outcomes. Comparative studies with conventional Ahmed placement, ideally randomized, would help determine whether retrobulbar placement offers superior outcomes, particularly regarding HP incidence and long-term success rates in high-risk populations. Although the absolute medication reduction was substantial, the high baseline medication burden (4.55 agents) should be considered when comparing the magnitude of medication reduction with other surgical series (typically 2.7–3.3 agents). The percentage IOP reduction (~44%) is consistent with Ahmed valve performance. The final IOP of 13.39 mmHg is better than typical AGV outcomes and comparable to Baerveldt, though this likely reflects the lower starting IOP rather than superior efficacy. Importantly, the final medication count of 1.87 agents is higher than what trabeculectomy with MMC typically achieves (0.4–1.3 agents), suggesting that if the goal is maximal medication independence, trabeculectomy remains superior.

Conclusion

In a predominantly Black/African American cohort of pseudophakic patients with refractory glaucoma, retrobulbar/intraconal placement of the Ahmed FP-7 valve with a tube extender produced meaningful IOP reduction, decreased medication burden, and stable visual fields at 12 months. The low incidence of documented hypertensive phase, compared with published rates of 56–82% reported with conventional placement, represents a potentially significant advantage of this technique. These results highlight the potential of retrobulbar/intraconal implantation to expand surgical options for patients with advanced or refractory glaucoma and warrant validation in larger cohorts with longer follow-up.

Disclosures

None.

References

- Stein JD, Khawaja AP, Weizer JS. Glaucoma in Adults—Screening, Diagnosis, and Management: A Review. *JAMA*. 2021. 325: 164-174.
- Kastner A, King AJ. Advanced Glaucoma at Diagnosis: Current Perspectives. *Eye*. 2020. 34: 116-128
- Gedde SJ, Feuer WJ, Lim KS, Barton K, Goyal S, et al. Postoperative Complications in the Primary Tube Versus Trabeculectomy Study During 5 Years of Follow-Up. *Ophthalmology*. 2022. 129: 1357-1367
- Won HJ, Sung KR. Hypertensive phase following silicone plate Ahmed glaucoma valve implantation. *J Glaucoma*. 2016. 25: e313-e317.
- Chang EK, Gupta S, Chachanidze M, Miller JB, Chang TC, et al. Combined pars plana glaucoma drainage device placement and vitrectomy using a vitrectomy sclerotomy site for tube placement: a case series. *BMC Ophthalmol*. 2021. 21: 106.
- Laroche D, Grodecki B, Grimes KR, Ng C. Retrobulbar/intraconal tube placement in patients with glaucoma: Ahmed FP-7 and tube extender case series with 1-year follow-up. *Front Ophthalmol*. 2025. 5:1408897.
- Fargione RA, Tansuebchueasai N, Lee R, Tania Tai TY. Etiology and management of the hypertensive phase in glaucoma drainage-device surgery. *Surv Ophthalmol*. 2019. 64: 217-224.
- Taylor AW. Ocular immune privilege. *Eye*. 2009. 23:1885-1889.
- Bailey AK, Sarkisian SR Jr. Complications of tube implants and their management. *Curr Opin Ophthalmol*. 2014. 25: 148-153.
- Ishida K, Netland PA. Ahmed Glaucoma Valve Implantation in African American and White Patients. *Arch Ophthalmol*. 2006. 124: 800-806.
- Nagar AM, Maghsoudlou P, Wormald R, Barton K, Hysi P, et al. Differences in the Surgical Outcomes of Glaucoma Surgery in Patients of African Caribbean Descent. *Curr Eye Res*. 2022. 47: 1567-1577.
- Christakis PG, Zhang D, Budenz DL, Barton K, Tsai JC, et al. Five-Year Pooled Data Analysis of the Ahmed Baerveldt Comparison Study and the Ahmed Versus Baerveldt Study. *Am J Ophthalmol*. 2017. 176:118-126.
- Lee CK, Ma KT, Hong YJ, Kim CY. Long-Term Clinical

- Outcomes of Ahmed Valve Implantation in Patients With Refractory Glaucoma. *PLoS One*. 2017. 12: e0187533.
14. Benagiano V, Rizzi A, Sannace C, Alessio G, Ribatti D, et al. Aqueous Humor as Eye Lymph: A Crossroad Between Venous and Lymphatic System. *Exp Eye Res*. 2024. 243:109904.
 15. Yücel YH, Johnston MG, Ly T, Patel M, Drake B, et al. Identification of Lymphatics in the Ciliary Body of the Human Eye: A Novel “Uveolymphatic” Outflow Pathway. *Exp Eye Res*. 2009. 89: 810-819.
 16. Johnson M, McLaren JW, Overby DR. Unconventional Aqueous Humor Outflow: A Review. *Exp Eye Res*. 2017. 158: 94-111.
 17. Sherman DD, Gonnering RS, Wallow IH, Lemke BN, Doos WG, et al. Identification of Orbital Lymphatics: Enzyme Histochemical Light Microscopic and Electron Microscopic Studies. *Ophthalmic Plast Reconstr Surg*. 1993. 9: 153-169.
 18. Jacobs SM, McInnis CP, Kapeles M, Chang SH. Incidence, Risk Factors, and Management of Blindness After Orbital Surgery. *Ophthalmology*. 2018. 125: 1100-1108.
 19. Sun PY, Leske DA, Holmes JM, Khanna CL. Diplopia in Medically and Surgically Treated Patients With Glaucoma. *Ophthalmology*. 2017. 124: 257-262.
 20. Laroche D, Calderon I, Nwokeji I. A novel retrobulbar/intraconal surgical approach with combined cataract extraction and a modified AHMED ClearPath 250mm2 tube in the ciliary sulcus with an inferior sclerotomy in black and Afro-Latino patients with advanced glaucoma: a 6-month retrospective study. *Front. Ophthalmol*. 2026. 6:1738832.
 21. Zhang Q, Liu Y, Thanapaisal S, Oatts J, Luo Y, et al. The Effect of Tube Location on Corneal Endothelial Cells in Patients With Ahmed Glaucoma Valve. *Ophthalmology*. 2021. 128: 218-226.
 22. Olayanju JA, Hassan MB, Hodge DO, Khanna CL. Trabeculectomy-Related Complications in Olmsted County, Minnesota, 1985 Through 2010. *JAMA Ophthalmol*. 2015. 133: 574-580.
 23. Budenz DL, Barton K, Gedde SJ, Feuer WJ, Schiffman J, et al. Ahmed Baerveldt Comparison Study Group. Five-Year Treatment Outcomes in the Ahmed Baerveldt Comparison Study. *Ophthalmology*. 2015. 122: 308-316.
 24. Shalaby WS, Myers JS, Razeghinejad R, Katz LJ, Pro M, et al. Outcomes of Valved and Nonvalved Tube Shunts in Neovascular Glaucoma. *Ophthalmol Glaucoma*. 2021. 4: 182-192.