

# Early Active Mobilization Following Extensor Tendon Repair in a Child: A Case Report

Ramandeep Kaur

General Surgery, 162MH, Assam, India

\*Corresponding author

Ramandeep Kaur, General Surgery, 162MH, Assam, India.

Received: October 14, 2025; Accepted: November 03, 2025; Published: November 08, 2025

## ABSTRACT

**Introduction:** Extensor tendon injuries in children are relatively uncommon but require precise repair and a well-monitored rehabilitation protocol for optimal outcomes. Early mobilization is considered beneficial in selected cases to prevent adhesions and stiffness.

**Case Presentation:** We report a case of a 6-year-old girl, left-hand dominant, who presented with a glass-cut injury over the dorsum of the left hand. Examination revealed a complete laceration of extensor tendons at Zone V. Surgical repair was performed using a modified Kessler core suture technique with an epitendinous running suture for reinforcement. Postoperatively, early mobilization was initiated on Day 3 using a dorsal protective splint, combined with controlled active extension and passive flexion exercises under supervision.

**Outcome:** The child showed excellent compliance and progressive improvement in range of motion. By 8 weeks, full active extension and flexion were achieved, with no extensor lag or stiffness. Functional outcome was satisfactory, and the child resumed full activity.

**Conclusion:** Early mobilization following extensor tendon repair using a child-adapted rehabilitation protocol can lead to excellent functional outcomes, even in pediatric patients. Strict splinting, guided therapy, and family involvement are key.

**Keywords:** Extensor Tendon Injury, Pediatric Hand Trauma, Early Mobilization, Tendon Repair, Zone V, Modified Kessler Technique

## Introduction

Extensor tendon injuries in children are infrequent due to protected play environments, but when they occur—typically due to lacerations—they pose significant challenges. Prompt diagnosis, meticulous repair, and appropriate postoperative rehabilitation are essential. Early mobilization protocols have shown promise in improving outcomes in adults [1, 2], and with proper adaptation and supervision, can be applied in pediatric cases as well. This case highlights the successful use of early mobilization in a young girl with a Zone V extensor tendon injury.

## Case Presentation

A 6-year-old girl, left-hand dominant, presented with a deep laceration over the dorsum of her left hand, sustained from a glass cut injury. The injury occurred while playing at home with a shattered window pane, and the child was brought to the hospital within 2 hours.

On examination, a 6 cm long, deep laceration was noted over the dorsal aspect of the left hand, with complete loss of active extension at the MCP joints of the index and middle fingers. Sensation and circulation were intact. Based on the anatomy, the extensor tendon injury was classified as Zone V.

Under general anesthesia, wound exploration confirmed complete transection of the extensor digitorum tendons to the index and middle fingers, with near-total laceration of the

**Citation:** Ramandeep Kaur. Early Active Mobilization Following Extensor Tendon Repair in a Child: A Case Report. J Ortho Physio. 2025. 3(4): 1-4.

DOI: doi.org/10.61440/JOP.2025.v3.45

extensor indicis. After haemostasis, tendons were repaired using the modified Kessler core suture technique with 5-0 Prolene, reinforced by a continuous epitendinous suture. The wound was closed in layers with 4-0 Monocryl and dressed. The hand was immobilized in a dorsal splint with the wrist in 25° extension, MCP joints in 20° flexion, and IP joints fully extended.

### Rehabilitation Protocol

On postoperative Day 3, early active mobilization was initiated under a physiotherapist's supervision:

- Passive flexion and active extension within splint (5–10 reps, 4–6 times/day)
- Place-and-hold exercises to encourage active engagement
- All exercises performed in a protective splint under parental supervision
- Sessions were made engaging with toys and games to improve compliance

### Outcome and Follow-Up

By postoperative Day 10, the child demonstrated improving motion without any suspicion of tendon adhesions or rupture. By Week 3, she achieved full active extension and flexion. No extensor lag, stiffness, or scar complications were noted. At 6 weeks, she resumed full hand function including fine tasks like writing and drawing. The final Modified TAM (Total Active Motion) score indicated >95% recovery.

### Discussion

Extensor tendon repair in children presents unique challenges due to smaller anatomy, variable compliance, and long-term functional concerns. While immobilization has been the traditional approach, early controlled mobilization is gaining support for its role in reducing adhesions and improving tendon glide [2,3,4].

In this case, the modified Kessler technique provided sufficient tensile strength to allow early motion. With structured supervision and parental involvement, the child achieved complete recovery without complications.

### Why Delayed Rehabilitation Is Traditionally Preferred in Children

Historically, delayed rehabilitation has been favored for several reasons:

- High healing potential: Children heal faster, reducing adhesion risk with immobilization [5].
- Compliance concerns: Young children (<8 years) may not reliably follow rehab protocols [6].
- Risk aversion: Extensor tendons remain under tension during extension, heightening rupture risk [7].
- Lower adhesion rates: Pediatric patients generally develop fewer adhesions than adults [8].

### Challenges of Early Rehabilitation in Children

- Limited cooperation and attention span require creative engagement and caregiver participation.
- Fear of pain may limit exercise participation.
- Splint intolerance and discomfort can affect adherence.
- Risk of overuse or re-injury during play is higher.
- Continuous multidisciplinary monitoring is essential for safe progress.

### How Early Rehabilitation Can Be Beneficial

Despite these concerns, early controlled motion offers clear advantages:

- Prevents adhesions and stiffness through enhanced tendon glide [3].
- Promotes faster functional recovery and proprioception [1].
- Reduces need for secondary procedures such as tenolysis [4].
- Improves psychological engagement by reducing fear and maintaining fine motor activity [9].

When the repair is strong (e.g., modified Kessler with epitendinous reinforcement) and supervision is consistent, early mobilization can yield superior outcomes without added complications [2]. Our patient's recovery reinforces this evidence: early rehabilitation, tailored to the child's maturity and family support, resulted in full functional recovery within 6 weeks.

### Conclusion

Early active mobilization following pediatric extensor tendon repair, when tailored to the child's needs and closely supervised, can lead to excellent functional recovery. This case supports the growing evidence for early movement protocols in select pediatric hand injuries.

### Patient Consent

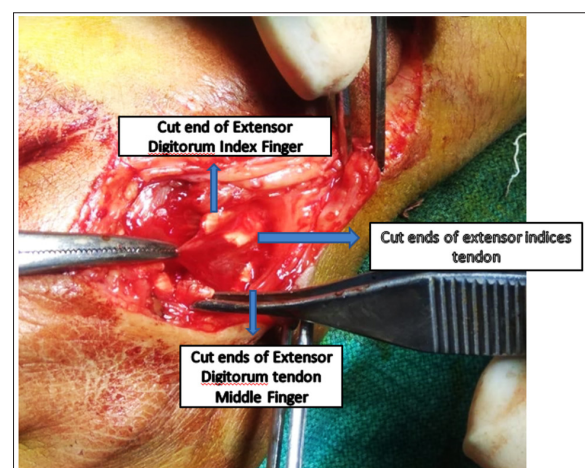
Written informed consent was obtained from the patient's parents for publication of this case report and accompanying images.

### Conflict of Interest

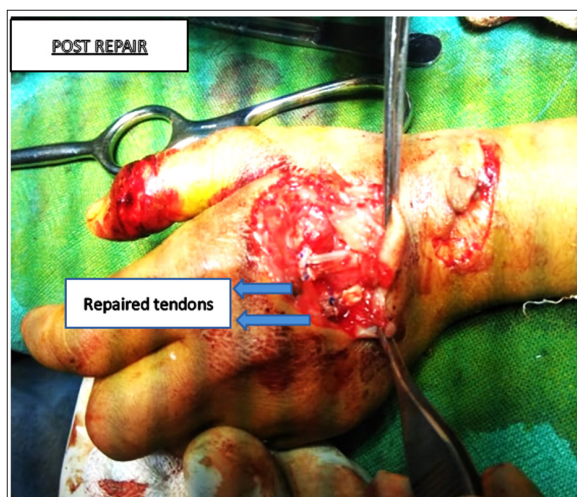
The authors declare no conflict of interest.

### Funding

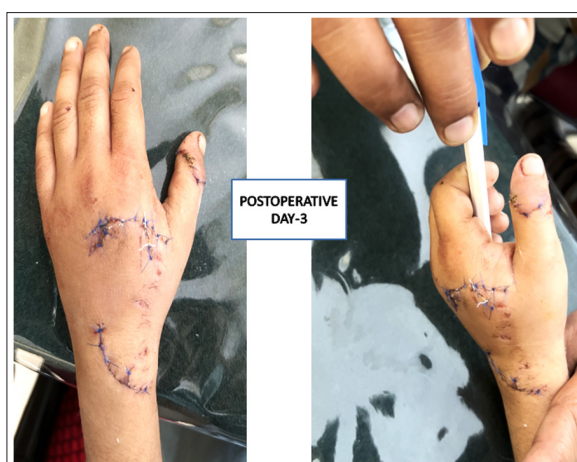This study received no specific grant from any funding agency in the public, commercial, or not-for-profit sectors.



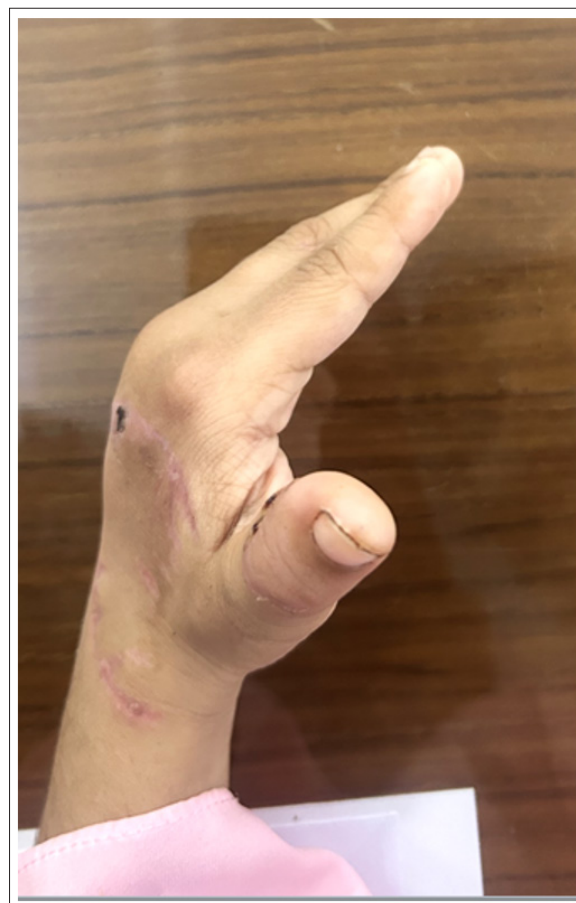**Figure 1:** Intraoperative view showing cut extensor tendons in Zone V before repair.



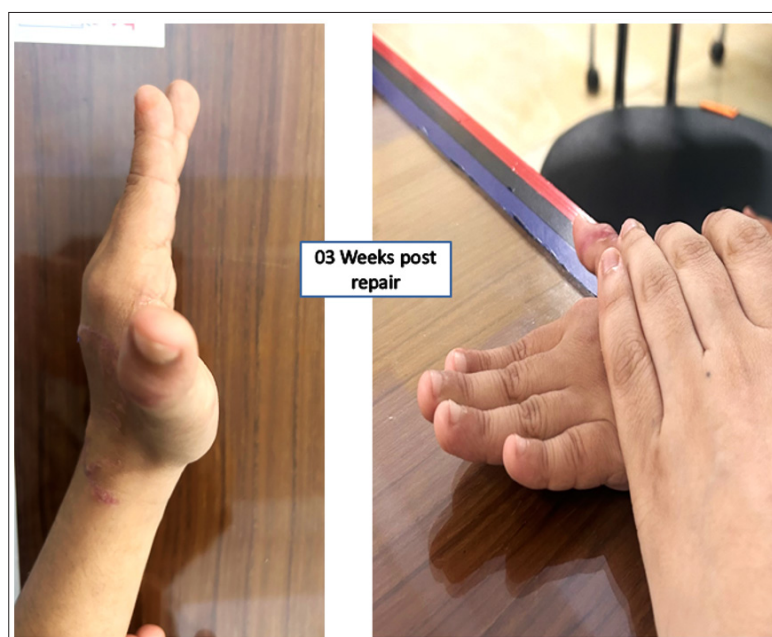**Figure 2:** Tendon repair performed using the modified Kessler technique with 4-0 Prolene and epitendinous reinforcement



**Figure 3:** Initiation of controlled passive and active range of motion exercises under physiotherapist supervision.



**Figure 4:** Range of extension of the left hand two weeks post-surgery showing progressive recovery.



**Figure 5:** Range of extension of the left hand three weeks post-repair, showing full restoration of movement.

**References**

1. Tang JB. Tendon Repair in the Hand: A Historical Review. Clin Orthop Relat Res. 2005. 431: 87-92.
2. Dy CJ. Evidence-Based Review: Rehabilitation Following Tendon Repair. J Hand Surg Am. 2012. 37: 829-835.
3. Thien TM, Becker C, Giessler GA. Early Controlled Mobilization after Extensor Tendon Repair in Zones V–VIII in Children. J Plast Reconstr Aesthet Surg. 2016. 69: 1102-1108.
4. Chow JA, Thomes LJ. Functional Results Following Primary Extensor Tendon Repairs. J Hand Surg. 1987. 12: 58-62.
5. Germann G. Pediatric Hand Injuries: A Review of the Literature. J Hand Surg (Eur). 2015. 40: 46-52.
6. Schnabl SM, et al. Postoperative Rehabilitation Protocols After Extensor Tendon Repair: Pediatric Compliance. Ann Plast Surg. 2019. 83: 441-446.
7. Nguyen MD. Outcomes of Extensor Tendon Repairs in Zones V to VIII. J Hand Surg Am. 2014. 39: 1726-1731.
8. van der Linden MH. Results of Extensor Tendon Repair in Children: A Retrospective Analysis. J Pediatr Orthop B. 2017. 26: 220-224.
9. Sunderland S, Ray WJ. The Psychological Aspect of Postoperative Rehabilitation in Children. Pediatr Surg Int. 2003. 19: 90-95.